

Radial Head Prosthesis Versus Internal Fixation In Treatment of Comminuted Fracture Head Radius in Adults

M.G.Al Ashhab, M.G.Montaser, A.I.Bakr, M.I.Mustafa and M.I.El Badawy
Orthopedic Surgery Dept., Faculty of Medicine, Benha Univ., Benha, Egypt
E-Mail: M.ElBadawy@gmail.com

Abstract

Spiral mind fractures are those the vast majority as a relatable point of the elbow fractures, (about 33% for elbow fractures) the range about spiral leader damages ranges starting with basic undisplaced fractures on comminuted fractures connected with other bony or ligamentous wounds. The vicinity about displaced alternately comminuted fractures ought to caution those specialist of the plausibility from claiming an copartnered ligamentous alternately hard damage. Those mossycup oak regular cohorted damages influence the coronoid, proximal ulna, those average Also parallel guarantee ligaments and the longitudinal radio ulna interosseous ligament. The point of this prospective examine might have been should assess the clinical Conclusion about cemented spiral leader prosthesis versus interior obsession for medication about comminuted crack of head span clinched alongside Grown-ups. This examine might have been directed starting with january 2016 on admirable 2019 including thirty grown-up patients for comminuted crack leader span (Mason iii -IV) Previously, Benha college healing facility What's more Jahraa healing center. Fifteen patients were dealt with Eventually Tom's perusing cemented spiral leader prosthesis (group An) Furthermore fifteen patients Toward interior obsession utilizing plates Also screws or screws (group B). As stated by Broberg and Morrey scores in assembly a (radial head prosthesis) for 15 instances we found phenomenal bring about 5 cases, useful bring about 9 cases, reasonable bring about person case, poor bring about 0 instance. In aggregation b (open diminishment Furthermore inside fixation) for 15 cases we found phenomenal bring about 2 cases, handy bring about 10 cases, reasonable bring about 3 cases, poor bring about 0 instance. We infer that bond undifferentiated Furthermore spiral head prosthesis supplanting will be superior to ORIF over medicine of masochistic kind iii and sort iv spiral head crack. The crack pieces passing blood supply Furthermore would at risk to corruption. Prosthesis reinstatement might exceptional restore the stability, flexion and development of the elbow, and the rotational movement of the lower arm.

Keywords: Mason III -IV, Radial head fractures, Fixation, ORIF.

1. Introduction

The spiral mind need progressively been found on assume a paramount part in the Strength of the elbow joint and also those lower arm [1]. Because of those intricate examine and biomechanics of the elbow joint spiral mind fractures need aid challenging, and especially the comminuted ones [2]. Fractures of the spiral leader Furthermore neck, which normally happen following a fall on the outstretched arm, represent 1. 5 % with 4% of know fractures Furthermore pretty nearly 33% for know elbow fractures [3]. To the extent that 85% of these fractures happen the middle of the third Furthermore sixth decade of age [4]. Spiral head fractures regularly happen Previously, companionship with different elbow fractures Furthermore delicate tissue wounds [5]. The The majority regularly utilized order about spiral leader crack will be recommended Toward masochistic [6]. As stated by this order spiral leader crack might a chance to be isolated under 3 types; a kind i crack is nondisplaced fracture, An sort ii crack may be a displaced fracture, What's more An kind iii crack may be a comminuted crack. Johnston included a fourth type, a spiral leader crack for disengagement of the elbow [4]. Point by point learning of the perplexing joint anatomy, biomechanics Furthermore agent methodologies need aid irreplaceable for dissecting What's more building a medication arrange [2]. In all the medicine about spiral leader fractures will be dependent upon those crack kind and the vicinity from claiming any copartnered damages [6].

Those point from claiming separated treatment methodology will be to restore those joint life systems What's more kinetics, stable What's more easy joint capacity and on dodge alternately no less than delay posttraumatic joint transforms [7]. Masochistic sort i fracture, ought further bolstering be figured out how without surgery. To Dealing with displaced spiral mind fractures [Mason sort II], moved forward strategies and more versant defiant need aided settle on protection additional attainable. Fantastic outcomes might make attained with open decrease Furthermore inner obsession [ORIF]. Mossycup oak clinician need personally encountered frustration with the medicine about spiral mind fractures from claiming masochistic kind iii [6]. Flimsy fractures of the spiral head usually happen Similarly as and only an intricate harm pattern, have pieces that need aid segregated Also versatile with little alternately no delicate tissue attachments Also would connected with bony What's more ligamentous damages of the elbow alternately lower arm. The essential objective about medicine may be will prevent disengagement alternately subluxation of the elbow Also lower arm with rebuilding of the radiocapitellar contact vital for arrangement Also Strength [8]. Those surgical alternatives to comminuted fractures incorporate ORIF, extraction Also substitution cost of the head. Extraction of the spiral head without supplanting to crack need An helter skelter muddling rate. A few critical difficulties are connected with spiral head extraction for example, such that side effects at those

wrist, increments elbow valgus Furthermore degenerative joint pain [6]. There may be absence of reasonable help proposals dependent upon strong confirmation in regards masochistic order sorts III- iv. Specifically master suppositions veer Also examine outcomes need aid conflicting. Particularly the worth for spiral head arthroplasty may be still hotly debated. [7]. Throughout previous years, the advancement of spiral head prosthesis need enhanced those clinical comes about from claiming this medication Also today On written works concentrated on as of late distributed bring been demonstrating greatly sure comes about [9].

2. Patients and methods

This study was conducted from January 2016 to August 2019 including thirty adult patients with comminuted fracture head radius (Mason III -IV) in Benha university hospital and Jahraa hospital. Fifteen patients were treated by cemented radial head prosthesis (group A) and fifteen patients by internal fixation using plates and screws or screws (group B).

2.1 Inclusion criteria

Sex: both sexes, Age group: adults older than 18 years and Mason type III and IV.

2.2 Exclusion criteria

Patients refused to join the study after explaining risks and benefits, associated vascular injury, Pathological fractures. Mason type I and II fracture head radius and previous elbow surgery or fractures.

2.3 Methods

All patients in this study were seen in orthopedic causality departments and were assessed both clinical and radiological prior to admission to the hospital as follow:

2.3.1 Primary clinical assessment

2.3.1.1 History

- Personal history : age, sex, occupation and special habits of medical importance(smoking)
- Past history : previous medical and surgical history (DM., cardiac, renal, peripheral vascular disease)
- History of injury: mechanism of injury, and time elapsed before presentation.

2.3.1.2 Clinical examination

- 1- General examination: vital signs, resuscitation, and head to toes examination.
- 2- Local examination:
 - Diagnoses of head radius fractures and other elbow injuries by the presence of any deformities, swelling, tenderness and limitation of movement.
 - Evaluation of overlying skin condition.

- Neurovascular status of the limb.

2.3.1.3 Radiological examination

- Antero-posterior, lateral radiographs of the affected elbow.
- CT scan evaluation was done in difficult fracture patterns.

2.4 Assessment of the outcome

2.4.1 Post-operative evaluation

- Clinical evaluation:
 - Range of motion.
 - Pain
 - Stability
 - Post operative complications.
- Radiological evaluation:
 - Antero-posterior, lateral radiograph.
- Follow up:
 - Patients were followed up two weeks postoperative, monthly for 6 month and every 6 month.
 - Functional assessment according to Elbow Functional Rating Index of Broberg And Morrey. The elbow functional rating index of Broberg and Morrey was used for assessment [10].

2.5 Assessment of healing in group B (fixation group)

Assessment of healing depends on clinical and radiological examination. Clinically patients were examined of any tenderness at lateral aspect of elbow, assessment any pain during elbow flexion and extension, forearm pronation and supination. Radiologically assessment healing depends on serial x-ray make every month AP, Lateral view for elbow to assess callus formation.

3. Results

Table(1) : show results of group A

- Flexion, mean 126.33 with range 100-135.
- Supination, mean 50.67 with range 40-60.
- Pronation, mean 54.76 with range 50-60.
- Broberg- morry points, mean, 90.27 with range 62-98.
- Excellent 5 cases (33.3 %)
- Good 9 cases (60 %)
- Fair 1 case (6.7 %)

Table (2) : show results of group B

- Flexion mean 120.33 with range 90-135.
- Supination mean 46.67 with range 10-60.
- Pronation mean 48.67 with range 20-60.
- Broberg- Morry points mean 86.73 with range 67-98.
- Excellent 2 cases (13.3 %).
- Good 10 cases (66.7 %).
- Fair 3 cases (20%).

Table(1) Results of group A (Radial head prosthesis)

Case	Gender	Age	Post. Op. Flexion	Post. Op. Supination	Post. Op. Pronation	Strength	Stability	Pain	Broberg-morrey (points)
1	Male	26	130	50	60	normal	normal	non	97
2	Male	26	120	40	60	normal	normal	mild	87
3	male	38	135	50	60	normal	normal	mild	91
4	female	64	100	40	50	Mild loss	normal	moderate	62
5	male	32	130	60	60	normal	normal	non	98
6	male	38	120	40	50	normal	normal	non	93
7	Female	62	130	50	60	normal	normal	non	97
8	male	25	130	50	50	normal	normal	mild	89
9	male	46	120	50	60	normal	normal	mild	88
10	male	42	130	60	50	normal	normal	non	97
11	male	37	135	60	60	normal	normal	mild	92
12	male	30	135	50	50	normal	normal	non	97
13	male	39	130	50	50	normal	normal	mild	89
14	female	40	120	60	50	normal	normal	mild	88
15	male	43	130	50	50	normal	normal	mild	89

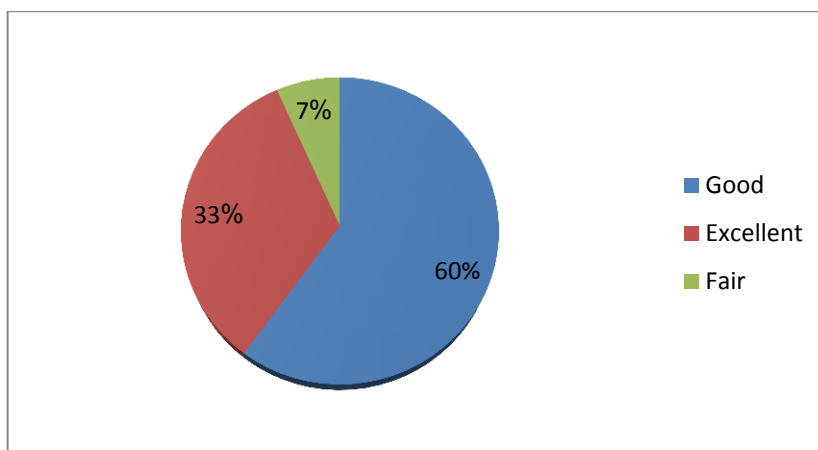


Fig (1) Distribution of results of Group A

Table (2) Results of group B (Open Reduction and Internal Fixation)

Case	Gender	Age	Post. op. Flexion	Post. Op. Supination	Post. Op. Pronation	Strength	Stability	Pain	Broberg-morrey (points)
1	female	36	130	50	50	normal	normal	mild	89
2	male	34	130	60	50	normal	normal	non	97
3	female	34	90	10	20	normal	normal	mild	74
4	female	51	100	40	40	normal	normal	mild	81
5	male	58	130	50	50	normal	normal	mild	89
6	male	26	130	60	60	normal	normal	non	98
7	male	41	120	50	50	normal	normal	mild	87
8	male	45	130	60	50	normal	normal	mild	90
9	male	50	120	40	50	normal	normal	non	93
10	male	53	130	50	50	normal	normal	mild	89
11	male	22	100	30	40	normal	normal	moderate	67
12	female	50	135	60	60	normal	normal	mild	92
13	female	50	110	40	50	normal	normal	moderate	71
14	male	31	130	60	50	normal	normal	mild	90
15	male	39	120	40	60	normal	normal	non	94

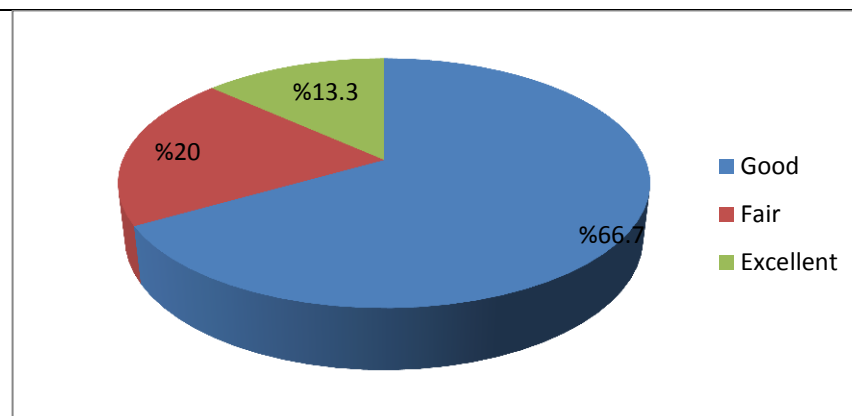


Fig (2) Distribution of results of Group B.

Table (3) Shows statistics of age and range of motion.

Independent Samples Test		Levene's Test for Equality of Variances	t-test for Equality of Means		p value	Mean Difference	Std. Error Difference	95% Confidence Interval of the Difference		
		F	Sig.	t				df	Upper	Lower
Age	Equal variances assumed	0.102	0.752	-0.522	28	0.605	-2.133	4.083	-10.498	6.231
	Equal variances not assumed			-0.522	27.803	0.606	-2.133	4.083	-10.501	6.234
Flexion	Equal variances assumed	2.549	0.122	1.393	28	0.175	6.000	4.308	-2.824	14.824
	Equal variances not assumed			1.393	24.175	0.176	6.000	4.308	-2.887	14.887
Supination	Equal variances assumed	5.041	0.033	0.990	28	0.331	4.000	4.039	-4.275	12.275
	Equal variances not assumed			0.990	20.673	0.334	4.000	4.039	-4.409	12.409
Pronation	Equal variances assumed	0.346	0.561	2.080	28	0.047	6.000	2.884	0.092	11.908
	Equal variances not assumed			2.080	21.088	0.050	6.000	2.884	0.004	11.996
Broberg-morrey (points)	Equal variances assumed	0.673	0.419	1.068	28	0.295	3.533	3.308	-3.243	10.309
	Equal variances not assumed			1.068	27.890	0.295	3.533	3.308	-3.244	10.310

Table (4) Show statistics study

Group	Broberg-Morrey points	Excellent	Good	Fair	Poor	Total
A	90.27	5(33.3%)	7(60%)	1(6.7%)	0(0)	15
B	86.73	2(13.3%)	10(66.7%)	3(20%)	0(0)	15

3.2 Discussion

Spiral head fractures would honestly normal damages showing of the orthopedic specialist. There bring been A large number investigations reporting weight those Conclusion for different systems for medicine for intense / dismissed spiral leader fractures. However, the current written works thinking about excision, obsession Also arthroplasty may be meager [10]. Poor

people prior effects of spiral head crack were most likely because of an insufficient Comprehension for anatomy, lesquerella refined systems Also likelihood the observation for widespread fulfillment for straightforward resection. On account of today's measures interest An more stupendous level for palatable function, ORIF is, no doubt generally used, Also spiral leader prosthesis substitution cost may be

utilized within those cases [6]. A percentage of writers accept that the spiral head is not a main significant part of the humeroradial joint, as well as for the solidness of the distal ulnar joint. For fractures of the spiral head, particularly comminuted with lower arm delicate tissue injury, proximal movement for a span seems every now and again and brings about wrist quality debilitating and unending elbow ache [12]. Over addition, spiral head crack may be frequently connected with other fractures from claiming elbow joint. What's more related elbow unsteadiness. Spiral head resection may be shown to be unsalvageable spiral head fractures connected with elbow unsteadiness [6]. The vitality of the spiral head. Also radiocapitate contact need been demonstrated both done clinical investigations. What's more experimentally, particularly after crack of the spiral head connected with ligament lesions. Those the vast majority basic reason for disappointment done open decrease. Furthermore inside obsession need been the failure to attain an stable osteosynthesis permitting right on time assembly [13]. The prosthesis might furnish a percentage component about stability, permitting initial restoration. A few writers accept that an arthroplasty with spiral head prosthesis, in any event in the short term, is safe. Furthermore successful alternative for those medicine for comminuted spiral head fractures [6]. Spiral head arthroplasty need been indicated with a dependable system to reproduction of the spiral head. Same time conceivably bewildered. Toward the truth that those spiral head fractures chose to arthroplasty tend with effect starting with higher vitality wounds for more comminution, the spiral head prosthesis interestingly were that's only the tip of the iceberg stable. Also needed a more stupendous room when contrasted with ORIF [14]. For our protocol for medicine about masochistic encountered with urban decay because of deindustrialization, engineering concocted, government lodgi sort iii fractures of the spiral head, ORIF will be performed at whatever point conceivable and addition stable. Similarly as to permit initial assembly. Previously, greatly comminuted fractures particularly though connected with lesions of the ligaments, the interosseal membrane, olecranon – coronoid fractures, dislocations of the elbow alternately fractures of the neck of the radius, we incline toward should settle on a prosthetic substitution, as these patients need aid the ones for more stupendous difficulties for osteosynthesis and the results turned extensively more awful.

The more seasoned eras about spiral head prosthesis units including the silicon implants didn't satisfy those biomechanical necessities of

the elbow joint, and in this way didn't get to be made. Concerning illustration an slandered medicine alternative. Since osteosynthesis might have been not an alternative to treating comminuted fractures because of its disappointment to enough restore dependability of the elbow, spiral head resection without an reinstatement arthroplasty of whatever kind stayed the standard agent method to comminuted fractures for a lot of people quite some time. [15]. However, resection includes an passing for strength which carries with it cohort difficulties for example, the proximal relocation of the span. What's more premature humeroulnar osteoarthritis [16]. Spiral head crack obsession may be an actually requesting technique. Investigations have demonstrated finer results for obsession at contrasted with extraction. Patients in whom the comminuted spiral head crack might have been treated for open diminishment. Also inside obsession needed acceptable joint motion, for more stupendous quality. What's more preferred capacity over those patients who needed under run spiral head resection. Obsession of comminuted spiral head fractures will be connected with a helter skelter rate for re-operation for hard ware evacuation alternately head extraction. Also carries a critical hazard of non-union [17]. Spiral head obsession ought to a chance to be endeavored in junior patients with insignificant comminution, in any case for appreciation that further surgery to fittings evacuation might make required. Utilizing low profile implants. What's more paying specific thoughtfulness regarding their positioning on the spiral head might be will minimize fittings difficulties [18]. Later investigations need turned out those points of interest of spiral head replacement, and there need not been any confirmation from claiming difficulties for example, such that osteoporosis of the span or disengagement that were specifically identified with the prosthesis supplanting. Absence of pertinent anatomic knowledge, blemished surgical instrument, what's more incompetent surgeons would the fundamental iatrogenic components that have prompted a unfavorable prognosis for spiral head fractures [18]. A portion surgeons accept that ORIF ought to a chance to be endeavored initially, accompanied by prosthesis reinstatement. On those beginning. Conclusion turns out unsuitable. Those withdrawal of close-by delicate tissue scares initiated toward various operations might bring about poor resultant capacity of the elbow. Repeatable surgical mediation might additionally build those danger from claiming heterotopic solidification. Due to these drawbacks, run Liu et al, favor spiral head prosthesis reinstatement to patients for

masochistic sort iii spiral leader crack [19]. Different implants are accessible for alternatives about monobloc or modular, monopolar alternately bipolar, cemented alternately uncemented and with straight alternately anatomically bended stems. There may be no reasonable proof in the present written works of the prevalence for one kind alternately insert through whatever available. Its paramount with get good the measure What's more tallness of the spiral leader insert. Utilizing a bigger extent insert and taking off it exorbitantly pleased brings about stiffness, ache What's more poorer results [20]. Utilization of an anatomic spiral leader insert prompts a great practical recovery, Actually in the vicinity from claiming extreme instability, for example, acases of coronoid crack Furthermore ULCL harm. Moreover, it need turned out successful for preserving elbow movement Furthermore administering those relative length of the span. However, patients ought further bolstering be educated of the secondary amount of unfriendly occasions Emulating this medicine [21]. An hazard of capitellar disintegration Furthermore osteopenia need been accounted for Emulating spiral leader reinstatement. This may be the vast majority regularly asymptomatic, Be that amendment might make necessary clinched alongside amazing cases from claiming disintegration. There is a helter skelter rate about stem-bone interface radiolucency seen for catch up of spiral mind displacements Furthermore it appears with be identified with prosthetic designs, which permit exactly stem development will permit congruency between the spiral leader Also capitellum All around those extent of movement [22]. There would a few issues worth consideration in the system about prosthetic reinstatement. In the osteotomy plane of the proximal span determines if those prosthesis fits or not. The osteotomised period of the proximal span must be balanced Appropriately. In it is a really short, the embedded prosthesis will a chance to be tight. In it is as well long, the embedded prosthesis will be unabated to reach for those capitellum What's more lose its preference. Second, useful pivotal arrangement of the spiral prosthetic stem ought further bolstering keep unpredictable revolution of the span Throughout pronation/supination. Those neck of the span makes a point about roughly 15 degrees restricting the spiral tuberosity with those in length hub of the proximal span. The prosthetic stem ought make in accord for the plot. Finally, management for ligament Also delicate tissue will be a basic step [23]. As stated by catch up range about movement clinched alongside bunch a (radial leader prosthesis) we analyze our result for run Liu et al [1], elbow

flexion Previously, run Liu might have been (133±1. 27) same time in our ponder elbow flexion will be (126. 33). Lower arm supination (79. 8±1. 73), same time clinched alongside our consider supination (50. 67). Lower arm pronation (73. 9±1. 12) same time over our contemplate pronation (54. 76). Previously, aggregation b (open decrease Also inward fixation) elbow flexion over run Liu might have been (135±1. 51) same time On our study elbow flexion may be (120. 33). Lower arm supination (81. 3±1. 13), same time over our examine supination (46. 67). Lower arm pronation (71. 3±1. 42) same time for our examine pronation (48. 67).

As stated by Broberg and Morrey scores for assembly a (radial leader prosthesis) we look at our aftereffect with run Liu et al, [1] done 37 situations they discovered phenomenal bring about 29 cases, useful bring about 7 cases, reasonable bring about person case, poor bring about 0 body of evidence. For our consider over 15 cases we discovered phenomenal bring about 5 cases, great bring about 9 cases, reasonable bring about you quit offering on that one case, poor bring about 0 case. Previously, gathering b (open decrease Also interior fixation) run Liu et al destroyed 35 cases they discovered fantastic bring about 24 cases, beneficial bring about 9cases, reasonable bring about 2 cases, poor bring about 0 instance. For our consider to 15 instances we discovered phenomenal bring about 2 cases, great bring about 10 cases, reasonable bring about 3 cases, poor bring about 0 instance. As stated by Broberg Also Morrey scores we think about those effect from claiming our examine What's more comes about of run Liu et al(1), Xiao chen et al(108) Furthermore Hong jr et al [6].

4. Conclusion

Those serum levels about HMGB1 need aid raised clinched alongside skin break out patients Also not associate for those sickness seriousness. Information regarding initial markers for example, HMGB1 might encourage finding about skin break out disease, screening those treatment, identification from claiming metabolic syndrome Previously, skin break out patients, Also distinguishing those effect metabolic syndrome need on the viability from claiming skin break out medicines.

References

- [1] Run Liu, Pengcheng Liu, , Comparison of primary radial head replacement and ORIF in Mason III fractures: A retrospective evaluation in 72 elderly patients. *Med Sci Monit*, Vol. 21, PP. 90-93, 2015.

- [2] K. Schmidt-Horlohe, S. Siebenlist, Fractures of the radial head and neck. *Z orthop unfall*. Dec, Vol. 149, PP. e69-86, 2011.
- [3] C. Nirmal, Tejwani, Hemang Mehata, Fractures of the head and neck: current concepts in management. *J Am Acad Orthop Surg*, Vol. 15, PP. 380-387, 2007.
- [4] M. Florian Kovar, Manuela Jandl, Incidence and analysis of radial head and neck fractures. *World J Orthop* April, Vol. 18;4, PP. 80-84, 2013.
- [5] GI. Bain, N. Ashwood, Management of Mason type III radial head fractures with titanium prosthesis, ligament repair, and early mobilization. *J Bone Joint Surgery Am*. Mar, Vol. 87, PP. 136-47, 2005.
- [6] Hong-Jian Ruan, Cun-Yi Fan, Jun-Jain Liu, A comparative study of internal fixation and prosthesis replacement for radial head fractures of Mason type III. *International Orthopedics (SICOT)*, Vol. 33, PP. 249-253, 2009.
- [7] J. Zwingmann, G. Bode, T. Hammer, Radial head prosthesis after radial head and neck fractures - current literature and quality of evidence. *Acta Chir Orthop Traumatol Cech*, Vol. 82, PP. 177-85, 2015.
- [8] D. Andrew Duckworth, R. Neil Wickramasinghe, Nicholas D Clement, Radial head replacement for acute complex fractures. *Clin Orthop Relat Res*, Vol. 472, PP. 2136-2143, 2014.
- [9] S. Giacomo, R. Michele, GH. Matteo, Surgical treatment of radial head isolated Mason III. *Injury, Int.J Care Injured* November, Vol.33, PP. 150-158, 2018.
- [10] MA. Brober, BF. Morrey, Results of delayed excision of the radial head after fracture. *J Bone and Joint Surgery*, Vol. 68A, PP. 669-674, 1986.
- [11] Vino Kumar, William Angus Wallace, Radial head fractures update on classification and management. *J. Orthopedic and Trauma* 26, Vol. 2, PP. 124-131, 2012.
- [12] Y. Rosenblatt, S. Athwal, KJ. Faber, Current recommendations for the treatment of radial head fractures. *Orthop Clin North Am*, Vol. 39, PP. 173-185, 2008.
- [13] P. Sanchez Gomez, F. Lajara Marco, Radial head comminuted fractures; a comparative study between resection and internal fixation. *Rev. esp cir orthop traumatol*, Vol. 5495, PP. 280-288, 2010.
- [14] Tyler Steven, MD. Watters, E. Grant, Garrigues, David Ring., Fixation Versus Replacement of Radial Head in Terrible Triad, is there a difference in elbow stability and prognosis. *Clin Orthop Related Res*, Vol. 472, PP. 2128-2135, 2014.
- [15] Arash Moghaddam, Tim Friedrich, Eike Dremel, Stefan Studier., (2016). Outcome of radial head arthroplasty in comminuted radial head fractures: short and midterm results. *Trauma Mon* February, Vol. 21, PP. e20201.
- [16] T. A mbacher, F. Maurer, K. Weise, Treatment results after primary and secondary resection of the radial head. *Unfallchirurg*, Vol. 103, PP. 437-43, 2000.
- [17] CP. Charalambous, JK. Stanley, SP. Mills, Comminuted radial head fractures: aspect of current management. *J Shoulder Elbow Surg*, Vol. 20, PP. 996-1007, 2011.
- [18] GR. Smith, RN. Hotchkiss, Radial head and neck fractures: Anatomic guidelines for proper placement of internal fixation. *J Shoulder Elbow Surg*, Vol. 5, PP. 113-117, 1996.
- [19] CA. Loreto, G. Rollo, V. Comitini, The metal prosthesis in radial head fracture: indications and preliminary results. *Chir Organi Mov*, Vol. 90, PP. 253-70, 2005.
- [20] DR. Shukla, JS. Fitzsimmons, Effect of stem length on prosthetic radial head micromotion. *J Shoulder Elbow urg*, Vol. 21, PP. 559-1564, 2012.
- [21] L. Tarallo, R. Mugnai, M. Rocchi, F. Capra, Mason type III radial head fractures treated by anatomic radial head arthroplasty: is this a safe treatment option?. *Orthopedics and Traumatology: Surgery and Research*, Vol. 103, PP. 183-189, 2016.
- [22] SW. O'Driscoll, JA. Herald, Forearm pain associated with loose radial head prosthesis. *J Shoulder Elbow Surg*, Vol. 21, PP. 92-97, 2012.
- [23] S. Smets, K. Govaers, N. Jansen, The floating radial head prosthesis for comminuted radial head fractures: a multicentric study. *Acta Orthop Belg*, Vol. 66, PP. 353-358, 2000.