

Management of Genu Varum in Adults with Medial Opening Wedge High Tibial Osteotomy using the Puddu Plate

Sh.A.Khalil, A.A.Ahmed, M.I. Mostafa and M.A.Yousif

Orthopedic Surgery Dept., Faculty of Medicine, Benha Univ., Benha, Egypt

E-Mail: mahmoud_aay@yahoo.com

.Abstract

Medial opening wedge high tibial osteotomy is one of the standard procedures used frequently to manage varus deformity of the knee through shifting the load laterally in the knee. To assess the safety and efficacy of opening wedge high tibial osteotomy using the puddu plate in patients with genu varum deformity This study was conducted on 22 knees in 20 consecutive patients who had performed medial opening-wedge high tibial osteotomy using Puddu plate between October 2017 and May 2019 for varus malalignment. This study was conducted in Benha university hospitals. The total knee society score was compared between preoperative and postoperative to assess the patients' outcome. Also individual elements of the score including alignment, instability and range of motion were assessed postoperatively. Varus angle and mechanical axis deviation were measured preoperative and postoperative. In this study, there was a significant improvement of knee society score post operatively. (P value <.00001). There was significant improvement of mechanical axis deviation with pre-operative mean 17.82 mm to post-operative -2.23 mm (valgus). (P value <.00001). Patients started partial weight bearing at 8 weeks, then, full weight bearing started at 12 weeks, most patients returned to work after 15 weeks. The findings of our study showed many benefits of medial opening wedge high tibial osteotomy with puddu plate procedure including easier procedure, no need for bone graft. This procedure had satisfactory outcomes regarding union rates pre and post-operative scores, patient satisfaction and low rate of complications.

Keywords: Genu Varum, High Tibial Osteotomy, Medial Opening Wedge, Puddu Plate.

1. Introduction

Frontal plane malalignment of the lower extremity results in abnormal load distribution across the knee joint. In genu varum deformity, the load distribution shifts medially, increasing the stress on the medial compartment. Consequences of the excess stress include cartilage injury, meniscus damage, ligamentous imbalance, and medial compartmental osteoarthritis. [1]

High tibial osteotomy is a widely accepted procedure to treat varus alignment of the knee associated with medial compartmental arthritis overload. Valgus producing proximal HTO shifts the mechanical axis of the lower limb from the medial compartment laterally, decreasing medial contact pressure, and contact area. Medial compartment unloading leads to reduced pain, improved function, and potentially reduces cartilage degeneration. Correct patient selection is fundamental in achieving good results. [2]

The ideal patient to perform HTO using the puddu plate aged below 60 years with unicompartmental osteoarthritis in the medial joint space, varus deformity less than 10 degrees with no flexion deformity and good patient motivation to comply with postoperative rehabilitation program. The benefits of this technique are the short time of operation in comparison to other techniques of corrective osteotomy, no casting postoperative because the puddu plate gives rigid fixation which lead to early range of motion to the knee. [3] The aim of this study was to assess the safety and efficacy of

opening wedge high tibial osteotomy using the puddu plate in patients with genu varum deformity.

2. Patient and methods

This was a case series study conducted on 22 knees in 20 consecutive patients who had performed medial opening-wedge high tibial osteotomy using Puddu plate between October 2017 and May 2019 for varus malalignment. This study was a multicenter study conducted in Benha university hospitals, Orthopedic & Spine hospital in Shebin El- Kom and Arab Contractors Medical Center after approval of the ethical committee of the hospital, a written consent was taken from every patient before participation in the study.

The Inclusion Criteria included medial compartment arthritis, varus knee malalignment, age group from 18 to 65, good range of motion (i.e., flexion > 90° and flexion contracture < 10°) and compliant patient that will be able to follow postop protocol.

The Exclusion Criteria included age less than 18 years and more than 65 years, combined medial and lateral arthrosis, flexion contracture more than 20 degrees, instability allowing the tibia to sublaxate more than 1 cm, significant patellofemoral disease, obese patients BMI >35 and prior lateral meniscectomy or lateral tibiofemoral cartilage damage.

Preoperative evaluation was done by thorough history taking, clinical examination of the knee and adjacent joints to evaluate the type of the deformity, degree of deformity, range of knee motion, stability of the knee, whether patient

unilateral or bilateral using the knee society score. Radiological examination was done by performing knee standing anteroposterior views and a true lateral radiograph for all patients. Long standing x-ray was done preoperative. The use of magnetic resonance imaging (MRI) to evaluate meniscal tears, cartilage lesions or ligament injuries in patients with osteoarthritis of the knee was done for patients complaining from mechanical symptoms such as giving way and catching with positive examination tests such as McMurray's test.

2.1 Surgical technique

Position the patient was supine on a radiolucent table with C-arm of an image intensifier set up opposite to the surgeon. The tourniquet was inflated. Diagnostic arthroscopy of the knee was carried out before the osteotomy in some patients to assess the relative integrity of the lateral tibiofemoral compartment and of the patellofemoral joint and also to treat any intra articular pathology if suspected.

In patients with ACL deficiency, ACL reconstruction was done in the same time before the osteotomy, with conventional techniques of ACL reconstruction with semitendinosus and gracilis grafts, with exception of tibial interference screw was left to be introduced after the osteotomy.

Exposure of the anteromedial aspect of the tibia was done through a vertical skin incision centered between the medial border of the anterior tibial tubercle and the anterior edge of the medial

collateral ligament (at line of medial border of patella) and extending 6–8 cm distally to the joint line. The investing fascia was incised and the pes anserinus was identified.

Under guidance of fluoroscopy, 2 k-wires were advanced at an appropriate oblique angle (20° to the tibial shaft) from the metaphyseal-diaphyseal junction of the medial proximal tibial cortex, which corresponds to a point just above the upper border of the pes anserinus. The lateral aiming point was the upper third of the proximal tibiofibular joint. The osteotomy was done, keeping the oscillating saw blade below and parallel to the guide wires to prevent intraarticular fracture. Distal tibial tuberosity osteotomy was done, then, a sharp osteotome was used to finish the osteotomy, preserving a lateral hinge of approximately 0.5 cm of intact bone Fig (1).

After adequate exposure of osteotomy line, osteotomy guide was removed and an appropriate plate was inserted inside the osteotomy line. Before fixing the plate, checking the mechanical axis must be done under C-arm imaging by using the center of femoral head and center of ankle joint as reference points to draw roughly the mechanical axis and assess the varus correction.

The proximally placed screws were not allowed to come in direct contact with the joint surface and should be parallel to the osteotomy Fig (2).

After that, the wound was closed in layers after good hemostasis, the knee was put into a hinged knee immobilizer if available, or above knee posterior slab.

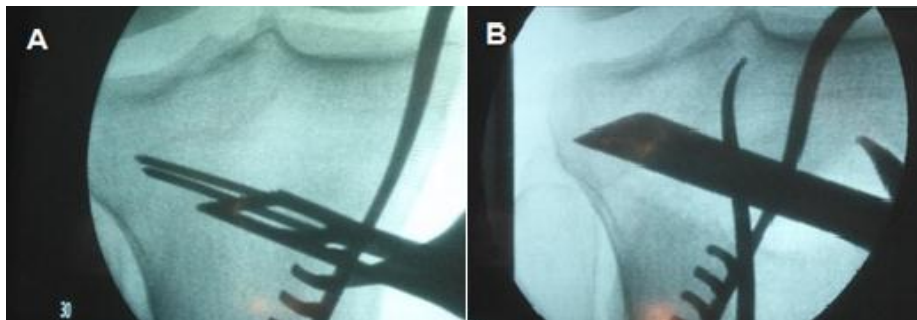


Fig (1) Osteotomy of the medial cortex with the saw (A) then using sharp osteotomes (B)

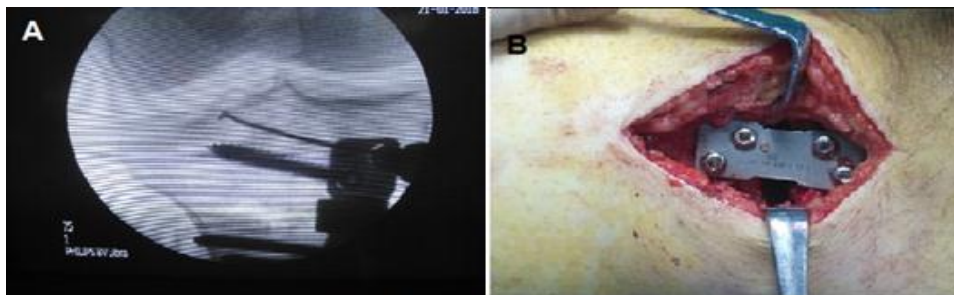

Fig (2) Plate positioning, with proximal and distal screws insertion.

2.2 Postoperative care and rehabilitation

The patients were non weight bearing for six weeks, after which they could begin partial then full weight-bearing when proper bridging callus formation were seen on X-ray. On the first postoperative day, the patient started isometric quadriceps exercises. The patients were rehabilitated with quadriceps muscle and hamstring strengthening exercises. Short radiographs were taken at six and twelve weeks to ensure maintenance of position and assessment of healing, and long leg alignment films done at six months to assess the correction achieved.

2.3 Outcomes

In this study, the total knee society score was compared between preoperative and postoperative to assess the patients’ outcome. Also individual elements of the score including alignment, instability and range of motion were assessed postoperatively. Varus angle and mechanical axis deviation were measured preoperative and postoperative.

2.4 Statistical Analysis

Data were collected, tabulated and statistically analyzed using an IBM personal computer with Statistical Package of Social Science (SPSS) version 22, IBM Corp, Armonk, NY, USA. Descriptive statistics for quantitative data presented as mean and standard deviation. Qualitative data presented as numbers and percentages (%). Data turned up to be non-normally distributed according to Kolmogorov-Smirnov test. Wilcoxon signed rank test was used to compare preoperative and postoperative scores. Mann Whitney U test was used to compare subgroups of the study group to assess the relationship between different factors and postoperative score. Two sided p value of (≤ 0.05) was considered statistically significant.

3. Results

This study comprised 20 patients with genu varum including 17 males and 3 females. The mean age of the patients was 35.77 ± 11.68 SD years and mean body mass index (BMI) was 27.91 ± 3.08 SD. The right side was affected in 11 patients, while the left side in 7 patients with 2 patients having bilateral affection (one patient was operated in the same setting while the other was operated in two settings with six months interval). In this study, the main chief complaint that made the patient sought medical advice was pain in 7 patients, deformity in 13 patients Table (1) .

Seventeen osteotomies were preceded by knee arthroscopy to assess the lateral compartment and to deal with other problems such as medial meniscal tears or osteoarthritic ulcers. Five of them were accompanied by ACL tear and ACL reconstruction was conducted using semitendinosus and gracilis tendons graft), Different puddu plate sizes were used ranging from 8 to 14, The puddu size was determined on basis of pre and intra-operative assessment of the varus deformity.

In this study, there was a significant improvement of knee society score post operatively. (P value $< .00001$) Regarding instability, measuring the maximum movement in any direction (antero-posterior or medio-lateral) in mm. There was significant improvement of outcomes post-operatively (P value = 0.00338). The range of motion improved with the osteotomies, measuring total range of flexion, mean ROM was 114.77 pre-operatively, which showed significant improvement post-operatively to become 118.91 (P value < 0.00001). There was significant improvement of mechanical axis deviation with pre-operative mean 17.82 mm to post-operative -2.23 mm (valgus). (P value $< .00001$) Table (2)

Table (1) Sociodemographic and clinical data of study group

Item	Mean	SD
Age	35.77	11.68
BMI	27.91	3.08
	No	%
Gender	Male	85
	Female	15
Side	Unilateral	90
	Bilateral	10
Complaint	Pain	35
	Deformity	65

In this study, the medial proximal tibial angle (MPTA) was measured pre-operatively with mean 84.23 which increased post-operatively to mean 94.55. The posterior tibial slope (PTS) was

measured on the lateral radiograph pre and post-operatively, which showed increase from mean 6.82 to 11.23 Table (3) .

Table (2) Comparison between preoperative and postoperative parameters

	Preoperative	Postoperative	Wilcoxon Signed test	P value
Knee society scores	75.59 ± 5.63	84.23 ± 3.56	z = -4.1069	< .00001
Instability	6.05± 6.14	2.95± 0.65	z = -2.9341	0.00338
ROM	114.77 3.16	118.91 2.69	z =-4.1069	< 0.00001

In this study, correction angle varied from 8 to 14 degrees, with mean 10.18, one knee was under corrected, 4 knees were neutrally corrected to 0 angle and 17 knees were overcorrected to valgus angle Table (4) .

In this study, Callus formation started to appear after 8 weeks (mean 8.09). Patients started partial weight bearing at 8 weeks (mean 8.27), then, full weight bearing started at 12 weeks (mean 12.27), most patients returned to work after 15 weeks (mean 15.27).

In regard of complications, one patients had infection, it was superficial infection of the wound, which appeared one month after the operation, It was treated by antibiotics (according to culture and sensitivity from wound swab), and repeated drainage. Two patients had intra-operative fracture of lateral cortex, the fracture was non displaced, after placing the puddu plate, It was managed conservatively by putting the patient in above knee cast and postponing the weight bearing till x-ray signs of union of lateral cortex.

Table (3) Comparison between preoperative and postoperative MPTA and PTS

	Preoperative	Postoperative	Wilcoxon Signed test	P value
MPTA	84.23 ± 1.45	94.55 ± 1.57	z = -4.1069	<0.00001
PTS	6.82± 2.72	11.23± 2.33	z = -4.1069	<0.00001

Table (4) Varus and corrective angels of study participants

	Min	Max	Mean	SD
Pre-oprative varus angle	6	11	9.14	1.7
Post-oprative varus angle	1	-3	-1.05	0.9
Correction angle	8	14	10.18	1.74

4. Discussion

The goals of high tibial osteotomy are pain relief, functional improvement, allowance of heavy functional demands, and extension of the functional life of the natural knee. [4] The surgical goal is correction of varus deformity, and to transfer the weight-bearing forces from the arthritic portion of the knee to a healthier location of the joint .

In the current study, 17 male patients and 3 female patients were included, mean age of patient was 35.77 years and mean body mass index (BMI) was 27.91. Previous study [5] reported that younger patients respond better and longer to realignment osteotomy, although others did not show a clear relationship between age of the patient and results of the osteotomy. Nowadays chronological age alone is not accepted as a criterion for eligibility. Bone texture, daily activity level, and biological age have a greater impact on selection criteria. Many studies [6] have

stressed the effect of local alignment on osteoarthritis occurring in respective compartments after analyzing 306 patients and 608 knees. They have found that one degree increase in varus angle was associated with increased risk of having medial compartment disease. Another study [7] had stated osteotomy as a reasonable option to treat active, physiologically young patients.

In this study, the high tibial osteotomy with puddu plate was done without using bone graft. Performing the osteotomy without graft is supported by many authors. A study [8] reported their results of healing of MOWHTO without bone graft.

Previous study [9] had compared grafted and non-grafted osteotomies in their prospective randomized clinical trial. There were no significant differences about bone union between the two groups. They demonstrated the lack of

benefits in adding this type of graft for the healing of the osteotomy.

This non-significant benefit for bone graft is consistent with biological reasoning, because the metaphyseal bone does not need full contact if there is rigid stability. [10] This is achieved by maintaining the integrity of the lateral tibial cortex, which functions as a fulcrum, from which formation of endosteal callus takes place, which progresses to the medial side of the osteotomy. [11]

Some surgeons [3] had used puddy plate and showed that these plates provided better stabilisation to maintain the wedge and early mobilisation. They [3] assessed 65 knees with osteotomies and found that it resolves pain and improves knee function significantly. But he has stressed that long term studies are required in elderly patients to know whether the results are satisfactory. Other authors [12] followed 93 cases with arthrosis of the medial compartment that had undergone open-wedge osteotomies for a median of 11.5 years, and reported that the results obtained were satisfactory up to 7 years postoperatively.

In the current study, we considered combined high tibial osteotomy and ACL reconstruction in ACL deficient varus knees in 5 patients to give functional stability for activities of daily living and possibly delay the progression of degenerative arthritis. Simultaneous procedure is preferred over staged procedure as it is short timed procedure that does not add much time to the total time of surgery and safe as it does not interfere with the tibial tunnel placement and at the same time it does not disturb postoperative rehabilitation program of the ACL.

Performing high tibial osteotomy in every ACL deficient varus knee is controversial. Some [13] agreed with doing the combined ACL reconstruction and correction of varus malalignment only in presence of varus thrust. A previous study [5] stated that ACL reconstruction in knees in this situation fails if varus alignment is not corrected. Also, they mentioned that varus alignment in an anterior cruciate ligament-deficient knee does not necessarily lead to a varus thrust and therefore varus mal-alignment does not always need operative correction.

Proponents for doing the combined procedure even in cases of primary varus mentioned that in the primary varus knee the lateral collateral ligament can become lax with time and varus thrust can consequently develop and on the long run medial compartment OA can develop. So, some [14] advised to combine ACL reconstruction with high tibial valgus osteotomy in every case ACL deficient varus knee.

In the current study, the mean medial proximal tibial angle increase 10.32. A previous study [15]

reported that the mean MPTA increase after OWHTO was 9.0. Another study [16] also reported that the mean increase in MPTA after OWHTO was 7.4. Another study [17] also reported a mean increase in MPTA of 10.4.

In the current study, the mean posterior tibial slope showed main increase of 4.41. A previous study [18] reported a significant increase in PTS of 4.2. Another study [19] found that PTS significantly increased from 5.3 preoperatively to 7.5 postoperatively. Another study [20] reported that PTS angle increased significantly from 8.0 preoperatively to 15.0 immediately postoperatively.

Theoretically, increased PTSA may raise anterior tibial translation and lead to increased tensile loads on the ACL. As a result, this may negatively influence ACL function and knee kinematics. Although some authors. [21] reported that an increase of less than 5° of posterior slope did not alter the in-situ forces on the ACL.

In the current study, one knee was undercorrected, 4 knees were neutrally corrected to 0 angle and 17 knees were overcorrected to valgus angle. This meets the reports of previous studies that recommended over correction. Some surgeons [22] recommended overcorrection in HTO in middle-aged patients, to effectively 'unload' the medial compartment. Some authors [23] stated that they had obtained successful results in varus or neutral (64%) and in 4 to 6 valgus (94%) positions. In a previous study [12], arthrosis did not deteriorate in patients maintained in 3 to 6 valgus position. Another study [24] found that the average loss of correction at 10 years post-operatively was 2.4°, explaining why patients experience good results only in the medium term.

In the current study, 19 patients had neither operative nor post-operative complications, while one patient had post-operative infection and two patients had fracture of the lateral cortex. Upon comparison, our results were similar to previous studies.

In a study [25] on 138 patients reported 18.8% overall complication rate in the form of infection, fracture and loss of correction. A study [26] on 58 patients reported 3.4% infection, 3.4% fracture and 1.7% loss of correction in their series of high tibial osteotomies. Another study [27] on 104 patients reported 2% infection and 25% fracture of lateral hing cortex. Another study [28] on 110 patients reported 3.6% infection rate in their patients.

A review of the literature [29] from the first description in 1958 to December 2013 was done. The review focused on the overall and specific complication rates associated with OWHTO, rather than the requirement for conversion to TKR or the correction angle achieved. Eighty-six

abstracts were identified and these were then refined to 24 papers that gave specific reference to complications resulting from the operation. The overall complication rate for MOWHTO reported in this review of literature ranges from zero to 37% (mean 15.6%). Of the 23 papers reviewed, excluding two single patient case reports, mean patient number was 89 (range 12 to 533), with follow-up varying from 0.5 to 5 years. Twelve papers declared an overall complication rate, yet only five of these reported on patient numbers above 50 with greater than one-year follow-up post OWHTO. [30] Of these five the mean overall complication rate was 12.3%. Few papers provided a comprehensive assessment of all potential complications with only 62% commenting on infection, 48% commenting on non-union and 33% on hardware irritation. [31]

This study was limited by the short follow-up period, small number of patients and absence of comparative group. A larger group of patients with long-term follow-up is needed to evaluate the long-lasting effects of HTO. However, early results obtained indicate that medial open-wedge osteotomies using Puddu plates could be realized safely with considerable success with encouraging outcomes.

5. Conclusion

The findings of our study showed many benefits of medial opening wedge high tibial osteotomy with puddu plate procedure including easier procedure, lesser exposure, no need for bone graft, obtaining more predictable correction, correcting the deformity close to its center and avoiding peroneal nerve and proximal tibiofibular joint injuries. This procedure had satisfactory outcomes in our study regarding union rates pre and post-operative scores, patient satisfaction and low rate of complications. However, achieving successful outcomes requires proper patient selection, effective planning, meticulous surgical techniques, and good rehabilitative programs.

References

- [1] W. Strecker. Planning analysis of knee-adjacent deformities. I. Frontal plane deformities. *Oper Orthop Traumatol* vol.18, pp.259-72,2006.
- [2] R.Rossi, D.E.Bonasia, A.Amendola. The role of high tibial osteotomy in the varus knee. *J Am Acad Orthop Surg.* Vol.19, pp.590-9,2011.
- [3] M.Asik, C.Sen, B.Kilic, S.B.Goksan, F.Ciftci, O.F.Taser. High tibial osteotomy with Puddu plate for the treatment of varus gonarthrosis. *Knee Surgery, Sports Traumatology, Arthroscopy* vol.14, pp.948-54,2006.
- [4] C.H.Flamme, O.Ruhmann, S.Schmolke. Long-term outcome following high tibial osteotomy with tension bend principle. *Arch Orthop Trauma Surg* vol.123, pp.12-16,2003.
- [5] D.D.Naudie, A.Amendola, P.J.Fowler. Opening wedge high tibial osteotomy for symptomatic hyperextension-varus thrust. *Am J Sports Med.* Vol.32, pp.60-70,2004.
- [6] F.A.Khan, M.F.Koff, N.O.Noiseux, K.A.Bernhardt, M.M.O'Byrne, D.R.Larson, K.R.Kaufman. Effect of local alignment on compartmental patterns of knee osteoarthritis. *The Journal of Bone and Joint Surgery.* American vol.90, pp.1961,2008.
- [7] M.A.Kelly, D.F.Dalury, R.H.Kim, D.Backstein. The new arthritic patient and nonarthroplasty treatment options. *JBJS.*vol.91, pp.40-42,2009.
- [8] A.Staubli AE, De Simoni C, Babst R, Lobenhoffer P. TomoFix: a new LCP-concept for open wedge osteotomy of the medial proximal tibia-early results in 92 cases. *Injury.* Vol.34, pp.55-62,2003.
- [9] A.R.Zorzi, H.G.da Silva, C.Muszkat, L.C.Marques, A.Jr.Cliquet, J.B.de Miranda. Opening-wedge high tibial osteotomy with and without bone graft. *Artif Organs.* Vol.35, pp.301-307,2011.
- [10] P.V.Giannoudis, T.A.Einhorn, D.Marsh. Fracture healing: the diamond concept. *Injury.* Vol.38, pp.S3-S6,2007.
- [11] A.E.Staubli, H.A.Jacob. Evolution of open-wedge high-tibial osteotomy: experience with a special angular stable device for internal fixation without interposition material. *International Orthopaedics.* Vol.34, pp.167-72,2010.
- [12] P.Hernigou, D.Medevielle, J.Debeyre, D.Goutallier D. Proximal tibial osteotomy for osteoarthritis with varus deformity: a ten to thirteen-year follow-up study. *J Bone Joint Surg Am.* Vol.69, pp.332-354,1987.
- [13] Y.Akamatsu, N.Mitsugi, N.Taki, R.Takeuchi, T.Saito. Simultaneous anterior cruciate ligament reconstruction and opening wedge high tibial osteotomy: report of four cases. *Knee.* Vol.17, pp.114-18,2010.
- [14] N.P.Badhe, I.W.Forster. High tibial osteotomy in knee instability: the rationale of treatment and early results. *Knee Surg Sports Traumatol Arthrosc.* Vol.10, pp.38-43,2002.
- [15] K.M.Lee, C.B.Chang, M.S.Park, S.B.Kang, T.K.Kim, C.Y.Chung. Changes of knee joint and ankle joint orientations after high tibial osteotomy. *Osteoarthritis Cartilage.* Vol.23, pp.232-38,2015.
- [16] K.J.Oh, Y.B.Ko, J.H.Bae, S.T.Yoon, J.G.Kim. Analysis of knee joint line obliquity

- after high tibial osteotomy. *J Knee Surg.* Vol.29, pp.649-657,2016.
- [17] K.Goshima, T.Sawaguchi, K.Shigemoto, S.Iwai, K.Fujita, Y.Yamamuro. Comparison of Clinical and Radiologic Outcomes Between Normal and Overcorrected Medial Proximal Tibial Angle Groups After Open-Wedge High Tibial Osteotomy. *Arthroscopy: The Journal of Arthroscopic & Related Surgery.* Vol.35(10), pp.2898-2908,2019.
- [18] A.Ducat, E.Sariali, B.Lebel, P.Mertl, P.Hernigou, Flecher et al. . Posterior tibial slope changes after opening-and closing-wedge high tibial osteotomy: a comparative prospective multicenter study. *Orthopaedics & Traumatology: Surgery & Research.* Vol.98(1), pp.68-74,2012.
- [19] H.Ogawa, K.Matsumoto, H.Akiyama. Effect of increased posterior tibial slope on the anterior cruciate ligament status in medial open wedge high tibial osteotomy in an uninjured ACL population. *Orthopaedics & Traumatology: Surgery & Research.* Vol.105, pp.1085-1091,2019.
- [20] O.Ozel, B.Yucel, S.Mutlu, O.Orman & H.Mutlu. Changes in posterior tibial slope angle in patients undergoing open-wedge high tibial osteotomy for varus gonarthrosis. *Knee Surgery, Sports Traumatology, Arthroscopy.* Vol.25(1), pp.314-318,2017.
- [21] J.R.Giffin, T.M.Vogrin, T.Santop, S.R.Woo, C.D.Harner. Effects of increasing tibial slope on the biomechanics of the knee. *Am J Sports Med.* Vol.32, pp.376-382,2004.
- [22] T.R.Sprenger, J.F.Doerzbacher. Tibial osteotomy for the treatment of varus gonarthrosis. Survival and failure analysis to twenty-two years. *J Bone Joint Surg.* Vol.85, pp.469-474,2003.
- [23] M.B.Coventry, D.M.Ilstrup, S.L.Wallrichs. Proximal tibial osteotomy. A critical long-term study of eighty-seven cases. *J Bone Joint Surg.* Vol.75, pp.196-201,1983.
- [24] G.Papachristou, S.Plessas S, J.Sourlas. Deterioration of long-term results following high tibial osteotomy in patients under 60 years of age. *Int Orthop.* Vol.30, pp.403-408,2006.
- [25] D.J.Chae, G.M.Shetty, K.H.Wang, A.S.Montalban Jr, J.L.Kkim, K.W.Nha. Early complications of medial opening wedge high tibial osteotomy using autologous tricortical iliac bone graft and T-plate fixation. *Knee.* Vol.18, pp.278-284,2011.
- [26] M.A.El-Assal, Y.E.Khalifa, M.M.Abdel-Hamid, H.G.Said, H.M.A.Bakr. Opening-wedge high tibial osteotomy without bone graft. *Knee Surg Sports Traumatol Arthrosc.* Vol.18, pp.961-966,2010.
- [27] R.Takeuchi. Fractures around the Lateral Cortical Hinge after a Medial Opening Wedge High Tibial Osteotomy: A New Classification of Lateral Hinge Fracture. *Arthroscopy.* Vol.28, pp.85-94,2011.
- [28] N.Reischl, P.Wahl, M.Jacobi, S.Clerc, E.Gautier, R.P.Jakob. Infections after high tibial open wedge osteotomy: a case control study. *Arch Orthop Trauma Surg.* Vol.129, pp.1483,2009.
- [29] T.Woodacre, M.Ricketts, J.T.Evans, G.Pavlou, P.Schranz, M.Hockings, A.Toms. Complications associated with opening wedge high tibial osteotomy-a review of the literature and of 15 years of experience. *The Knee.* Vol.23, pp.276-282,2016.
- [30] E.K.Song, J.K.Seon, S.J.Park, M.S.Jeong. The complications of high tibial osteotomy: Closing vs Opening Wedge. *J Bone Joint Surg (Br).* Vol.92, pp.1245-1252,2010.
- [31] G.Spahn, S.Kirschbaum, E.Kahl. Factors that influence high tibial osteotomy results in patients with medial gonarthrosis: a score to predict the results. *Osteoarthritis and cartilage.* Vol.14, pp.190-195,2006.